THE ACUTE
ABDOMINAL RADIOGRAPH

OBSTRUCTION OF THE BOWEL

THE PLAIN FILM SIGNS

LISA FIELD

QUIZ TIME !!!!!

FILM A

FILM B

FILM C

FILM D

FILM E

FILM F

FILM G

AIMS

- To recognise plain film radiographic signs of obstruction of the bowel.

OBJECTIVES

- Look at the distinguishing features of the small & the large bowel.
- What is obstruction?
- Causes of small & large bowel obstruction.
- Reporting the plain film abdomen.
- Radiographic signs of bowel obstruction.

CAUSES OF ACUTE ABDOMINAL PAIN

- NSAP
- Appendicitis → 75%
- Cholecystitis
- Urinary Tract
- Gynaecological
- Small Bowel Obstruction
- Perforated Peptic Ulcer
- Pancreatitis
- Diverticular Disease
- Trauma
- MANY OTHERS !!!!

How to report the abdominal film

Systematic review

The Plain Film Abdomen

- The supine abdominal radiograph is probably the single most useful examination as it allows the distribution of gas and the calibre of the bowel to be assessed.

(Sutton 2003)

POINTS TO CONSIDER

- Always check the anatomical marker.
- Look at the shape of the bowel.
- Distinguish between large & small bowel.
- Is the bowel distended ?
- Too small/ too large
- Visible or not visible
- Distorted / displaced
- Is there extra-luminal (free) gas ?
- Is the bowel gas in the correct place ?
- Are there any fluid collections ?
- Abnormally calcified
- Lung changes.

POINTS TO CONSIDER

- When describing the appearance of the gas shadows on an abdominal radiograph, the term "non-specific abdominal gas pattern" should be abandoned.

(Sutton 2003)

The Plain Film Abdomen

- Plain films can be misleading in 10-20% of overall examinations.

Sutton (2003)

- The diagnostic sensitivity can be increased by correlating the radiographic appearances with clinical information.

Gore and Levine (2000)

The Plain Film Abdomen

- The main problem when interpreting bowel dilatation lies in distinguishing the small bowel from the large bowel.

Begg (1999)

- Differentiating features depend upon the size, distribution and marking of the loops.

(Gore and Levine 2000)

Large or small ???

	SMALL BOWEL	*LARGE BOWEL*
HAUSTRA	ABSENT	PRESENT
VALVULAE CONNIVENTES	PRESENT IN JEJUNUM	ABSENT
NUMBER OF LOOPS	MANY	FEW
DISTRIBUTION OF LOOPS	CENTRAL	PERIPHERAL
RADIUS OF CURVATURE	SMALL	LARGE
DIAMETER OF LOOP	3-5cm	5cm+
SOILD FAECES	ABSENT	MAY BE PRESENT

HAUSTRA

- Haustra are distinguished from valvulae conniventes because they are thicker & further apart.
- Haustra tend to be 2-3mm wide and occur at intervals of 1cm, whereas the valvulae conniventes are 102mm wide and occur at intervals of 1mm.

HAUSTRA

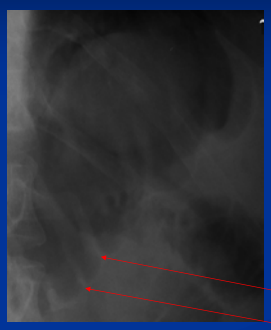

- Haustral folds may be seen partially across part of the large bowel lumen.
- Complete crossing of the lumen can occur.
- Haustra may be absent in the descending and sigmoid colon.

VALVULAE CONNIVENTES

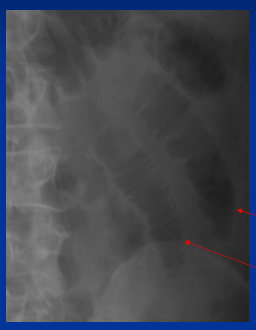

- The gas filled small bowel is distinguished from the colon by its smaller calibre and typical mucosal folds, which are usually thin and extend across the entire lumen of the bowel.

VALVULAE CONNIVENTES

- Valvulae conniventes are most numerous proximally and progressively disappear in the distal ileum. In the jejunum the valvulae conniventes are prominent and deep producing a more feathery appearance.

(Davis and Houston 2002)

Dilation of the Bowel

- Small bowel is dilated when it exceeds 2.5-3 cm
- Colon is dilated when it exceeds 5cm
- Caecum when it exceeds 8cm

(Brant and Helms 1999)

NUMBER AND DISTRIBUTION OF LOOPS

- Small bowel obstructions are identified by their central loop distribution.
- The distribution of the distended loops depends on the size of obstruction.

NUMBER AND DISTRIBUTION OF LOOPS

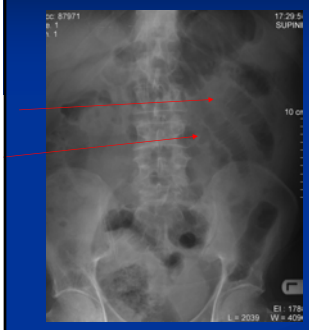

- When there are few loops of dilated bowel then the obstruction is of the proximal or mid-bowel.

NUMBER AND DISTRIBUTION OF LOOPS

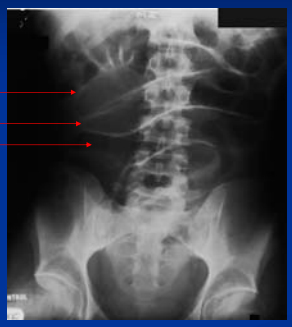

- If there is a distal small bowel obstruction, more dilated loops of bowel are demonstrated.

FAECES

- The adult colon almost always contains some gas and faecal material.
- The presence of solid faeces is the only reliable sign of distinguishing between small and large bowel.

WHAT IS OBSTRUCTION?

What is Obstruction?

- Mechanical bowel obstruction means stasis of the bowel due to occlusion of the lumen by a mass, stenosis from intrinsic bowel disease, or compression by extrinsic disease.
- The obstruction can be partial or complete.

(Brant and Helms 1999)

Small Bowel Obstruction

- Small bowel obstructions account for 20% of surgical admissions and 80% of all intestinal tract obstruction.

(Sutton 2003)

- Diagnosis of small bowel obstruction is made in 60-70% of cases from plain films.

(Grainger & Allison 1997)

Causes of small bowel obstruction.

STONE (gallstone ileus)
H ERNIA (21%)
A DHESION (49%)
V OLVULUS
I NTUSSUSCEPTION
T UMOUR (16%)

SHAVIT

PARALYTIC ILEUS

- More loops are dilated with this condition than with obstruction.
- Clinically a paralytic abdomen is characterised by a "silent abdomen".

Sutton (2003)

CAUSES OF PARALYTIC ILEUS

Pancreatitis
Pendicitis
Peptic ulcer
Perforation
Peritonitis
Pneumonia
Porphyria
Postoperative
Potassium deficiency
Pregnancy
Pyelonephritis

GALLSTONE ILEUS

- The terminal ileum is usually affected.
- A visible stone is seen in 30% of cases, measuring up to 2.5 cm in diameter.
- The bile duct may be outlined & dilated or there may be air in the lumen of the gall bladder.

Rigler's Triad

- Specific radiological signs may be present in nearly 40% of cases.
- Gas in the biliary tree (67%)
  Dilated loops of small bowel (80%)
  Visible ectopic gallstone (50%)

Plain film signs of bowel obstruction

Small Bowel Obstruction

- Small bowel pathology radiologically manifests as an accumulation of gas and fluid due to functional or mechanical obstruction.
- The site of most small bowel obstruction is the distal ileum.

SMALL BOWEL OBSTRUCTION

- Multiple, central loops of distended bowel with gas evident.
- Visible outlines of the mucosal folds crossing the entire lumen in places.
- Presence of multiple fluid levels on an erect film.

AIR -FLUID LEVELS IN THE SMALL BOWEL

- Normal air-fluid levels within the small bowel should not exceed 2.5 cm in length.

Begg (1999)

- The longer the duration of the obstruction, the greater the manifestation of fluid will be.The presence of fluid levels is not pathognomonic of bowel obstruction.

(Brant and Helms 1999)

CAUSES OF AIR-FLUID LEVEL ON ERECT ABDOMINAL RADIOGRAPHS

ILEUS
OBSTRUCTION
GASTROENTERITIS
ISCHAEMIA
HYPOKALAEMIA OR URAEMIA
NORMAL (< 2.5 cm IN LENGTH)

STACK OF COINS/ COILED SPRING SIGN

THE "STEP LADDER"/ "HAIRPIN" LOOP SIGN

- As more loops of bowel become distended, they appear to be stacked on top of each other in a characteristic " stepladder configuration.

(Nevitt 2000)

THE "STEP LADDER"/ "HAIRPIN " LOOP SIGN

- Intestinal distension can produce a "stepladder" or "hairpin" loop radiographic pattern.

Davis and Houston (2002)

SENTINEL LOOP

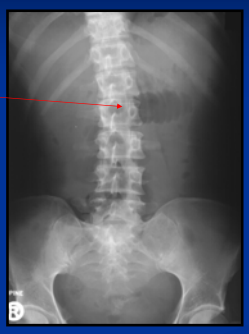

- It is a short segment of adynamic ileus that appears as an isolated loop of distended intestine that remains in the same position on serial radiographs.

THE SENITNEL LOOP

- An ileus maybe localised to a segment of bowel due to a focal inflammatory process.
- It can suggest certain inflammatory conditions in organs adjacent to the small bowel loop affected.

POSTION OF THE SENITNEL LOOP	ASSOCIATED PATHOLOGY
LEFT UPPER QUADRANT	PANCREATISIS PYELONEPHRITIS SPLENIC INJURY
RIGHT UPPER QUADRANT	ACUTE CHOLECYSTITIS HEPATITIS PYELONEPHRITIS
LOWER QUADRANTS	DIVERTICULOSIS APPENDICITIS SALPINGITIS CYSTITIS CROHN'S DISEASE

STRING OF PEARLS SIGN

Lateral Decubitus Radiograph

- The sign refers to a row of small bubbles of gas that are trapped between the valvulae conniventes with the remainder of the bowel loop filled with fluid.

(Davis and Houston 2002)

STRING OF PEARLS SIGN

- The string of pearls sign is considered to be virtually diagnostic of a small bowel obstruction. (Sutton 2003)
- Therefore this sign may indicate the presence of small bowel obstruction on horizontal beam radiographs when supine radiographs are indeterminate. (Nevitt 2000)

LARGE BOWEL OBSTRUCTION

Causes of large bowel obstruction.

- Carcinomas
- Diverticular disease
- Volvulus – sigmoid + caecum
- Inflammatory bowel disease
- Appendix abscess
- Metastasis
- Lymphoma
- Pelvic mass

Large Bowel Obstruction

- In the United Kingdom 60% of large bowel obstruction are caused by tumours. (Adenocarcinomas) Begg (1999)
- However in other countries torsion of the bowel (volvulus) is the most common cause. (Sutton 2003)

Large Bowel Obstruction

- Large bowel obstruction is predominantly seen in older adults, accounting for 20% of all bowel obstruction.

Brant and Helms (1999)

- The obstruction usually occurs in the sigmoid colon, where the bowel tends to have a narrower calibre and the stool is more solid.

(Gore and Levine 2000)

Large Bowel Obstruction

- Perforations of the colon have been reported in as many as 7% of all large bowel obstructions .

LARGE BOWEL OBSTRUCTION DUE TO DIVERTICULAR ABCESS

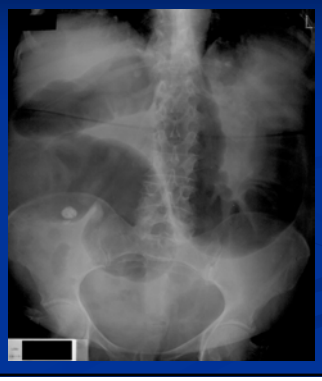

Large Bowel Obstruction

- A distended large bowel can demonstrate a number of appearances radiographically depending on the position of the obstruction and whether or not the ileocaecal valve is competent.

Begg (1999)

Large Bowel Obstruction

- If the valve is competent the cecum will distend and if the valve is not competent then the backpressure will be transmitted into the small bowel causing distension of the small bowel without caecal distention.
- When the caecum exceeds 10 cm in diameter it is at high risk of perforation.

(Sutton 2003)

The Importance of the Ileocecal Valve in Large Bowel Obstruction.

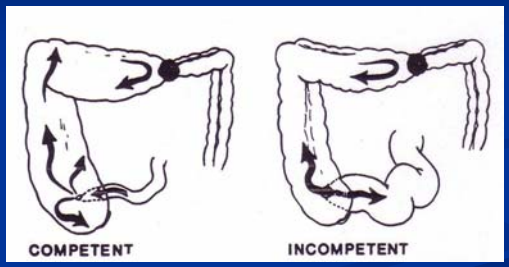

SIGMOID & CAECAL VOLVULUS

- This occurs where the mesentery of the gut is longest, the most common sites being the sigmoid colon and the caecum.

CAECAL VOLVULUS

- Less common causing only 1-3% of large bowel obstruction in adults.
- The mortality rate is 20-40% and is usually due to a delay in diagnosis.
- Approximately 60-75% of cases of colonic volvulus involve the sigmoid colon and has a reported mortality of 20-25%.

SIGMOID VOLVULUS

- The three radiographic signs, apex of loop under the left hemi-diaphragm, inferior convergence on the left and the left flank overlap sign were 100% specific in the diagnosis of sigmoid volvulus.

THE COFFEE BEAN SIGN IN SIGMOID VOLVULUS

- It is the compression of the 2 walls of the bowel that produces the "coffee bean" sign.
- A lack of haustra within the dilated loop is evident.

PSEUDO- OBSTRUCTION

- Distention of the small & large bowel without obstructing lesion.
- Similar in appearance to ileus.
- It is associated with medical conditions such as MI (myocardial infarction), pneumonia and myxoedema.

(Begg 1999)

SUMMARY

- Survey the film initially without clinical information, so a full objective unbiased evaluation can be considered.
- Small fluid levels can occur normally.
- Always consider a differential diagnosis.

SUMMARY - SBO

- The small bowel only becomes well visualised with abnormality.
- Look for the valvulae conniventes.
- The small bowel is central and contains fluid & gas.
- The more distal the obstruction the more loops will be distended.
- The longer the duration of obstruction the bigger the fluid levels.

SUMMARY - LBO

- The colon is peripheral and contains faeces.
- Look for dilated loops >5 cm.
- Look for haustral folds.
- Look for fluid/faeces on erect films.
- Look for distention of the small bowel indicating the ileocacecal valve competency.

Small or Large ? Plain Film Radiography

Synergy April 2005 Page 4-8.
By Lisa Field

ANSWERS

- FILM A – Patient presented with vomiting, distention and central abdominal pain.
- Distal small bowel obstruction.

ANSWERS

- FILM B – Patient presented with acute abdominal pain & vomiting.
- Proximal small bowel obstruction.

ANSWERS

- FILM C – Patient presented with severe abdominal pain. Increased bowel sounds and absence of bowel movement or flatus.
- Distal small bowel obstruction.

ANSWERS

- FILM D - Patient presented with increased abdominal pain & bowel sounds with absence of flatus. Patient has history of diverticular disease.
- Large bowel obstruction due to diverticular abscess.

ANSWERS

- FILM E – Patient presented with severe abdominal distention and pain. Long standing problems of constipation. PR examination concludes empty rectum.
- Sigmoid Volvulus.

ANSWERS

- FILM F – Patient has severe left loin pain with haematuria and fever.
- Sentinel Loop with possible local inflammation.
- Pyelonephritis.

ANSWERS

- FILM G – Patient presented with increased abdominal pain. Clinically there were reduced bowel sounds.
- Distal small bowel obstruction / paralytic ileus.
- Patient has had an ileo pouch anal anastomosis.